

Advanced Transvaginal 3D/4D Imaging of the Uterine Cavity Paves the Way for Ultrasound Hysteroscopy

Bill Smith

Clinical Diagnostics Services, London, UK

Introduction

The development of transvaginal scanning (TVS) in the early 1980s had a major impact in terms of ultrasound examination of the female pelvis. It remains the principal imaging modality for assessment of the pelvic organs and associated gynaecological disorders. The diagnostic value of TVS and its major influence on clinical managements have been well documented.

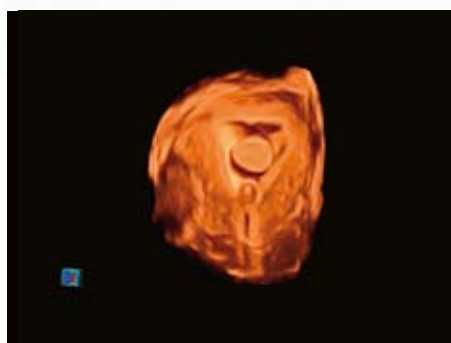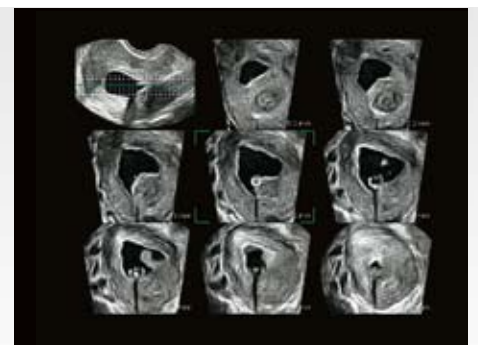
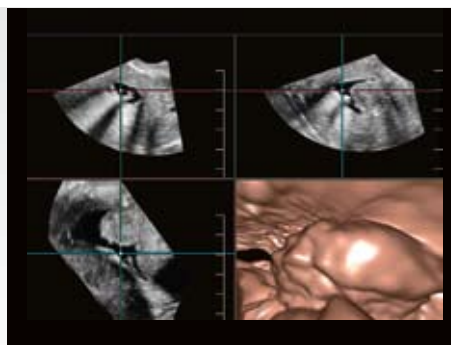
The pioneering work of Smith, Craft et al (London) promoted the use of TVS in reproductive gynaecology, particularly as part of IVF and assisted reproduction techniques, from 1982 onwards. The role of TVS rapidly expanded to include aspects of general gynaecology and early pregnancy

assessments. Extensive work carried out by Smith, McMillan, Farrugia, O'Riordan et al (London) in the early 1990s focussed on the benefits of TVS specifically in the investigation of abnormal uterine (post-menopausal) bleeding. TVS became an integral part of patient investigation at hysteroscopy outpatient clinics set up by the above personnel at North Middlesex Hospital and Whipps Cross Hospital, London.

The idea of transcervical infusion of saline in order to distend the uterine cavity presented obvious advantages in terms of outlining the size and shape of the cavity and demonstrating associated pathologies. The technique of saline infusion sonohysterography (SIS), or fluid ultrasound, was

established by Smith and O'Riordan as part of the above clinics. On-going work over several years at that early stage confirmed increasing favourable levels of correlation between (2D TVS) SIS and hysteroscopic findings.

The role of TVS SIS techniques was significantly enhanced with the introduction of 3D ultrasound imaging. The ability to rapidly acquire a 3D volume and easily recall and manipulate the stored ultrasound data has proven to be of tremendous practical and clinical value. It was very quickly realised that 3D interrogation of the uterine cavity produced very precise imaging of its internal features once distended by saline. More recent advances in surface rendering techniques have further increased



the diagnostic capability of SIS examination. The very latest, state of the art Toshiba Medical Systems has moved TVS 3D/4D technology on yet another step – the Aplio 500 series provides the capability of Fly Thru ultrasound imaging thereby creating the true concept of ultrasound hysteroscopy.

Materials and methods

SIS is now an established procedure in many leading units. It is regarded as an integral part of TVS ultrasound and in experienced hands proves to be a relatively quick and simple technique. The whole procedure takes approx. 10–15 minutes on average which includes only a comparatively short time involving the ultrasound imaging process itself.

A simple clinical procedure set is required (figure 1a) and the technique utilises some form of narrow, soft balloon catheter (figure 1b). The catheter is carefully introduced transcervically using a vaginal speculum and gently inserted so the tip of the catheter lies within the cervical canal or lower uterine cavity. Approx. 1–2 ml of saline is then used to inflate the balloon in order to fix the position of the catheter and prevent backflow of saline solution.

Normal saline is slowly injected and distension of the uterine cavity visualised under real time TVS control. Typically 10–20 ml of saline is required for most examinations. Injection of saline is halted at selected stages, dependent upon the degree of cavity dilatation and/or the area or structure to be

examined, and a 3D volume acquisition or ultrasound sweep is carried out. The multiplanar image obtained (figure 2a) is reviewed and, if adequate, stored on to the system hard-drive. The procedure is then continued.

It is crucial that the 3D system functions are easy to use with very rapid acquisition, storage and retrieval of ultrasound data. In addition, it should be stressed that the image quality achieved totally reflects the basic 2D (grey scale) performance of the ultrasound unit and correct utilisation of both 2D and 3D controls and presets.

On completion of the procedure, the acquired 3D ultrasound information can then be retrieved and

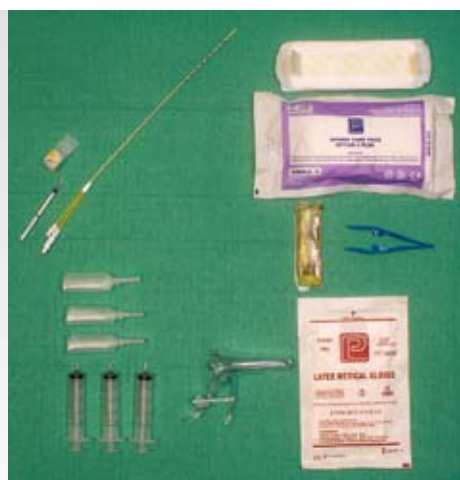

Fig. 1a: The basic clinical trolley setting showing the SIS balloon catheter, syringes and ampoules of saline, speculum, sponge holding tweezers, cleansing fluid and dressing pack.



Fig. 1b: Close-up of the inflated balloon on typical catheters used for SIS procedure.

Figures 2:

Examples of typical image formats obtained from a single 3D sweep. These can be easily displayed pre- or post storage of acquired volumetric ultrasound data.

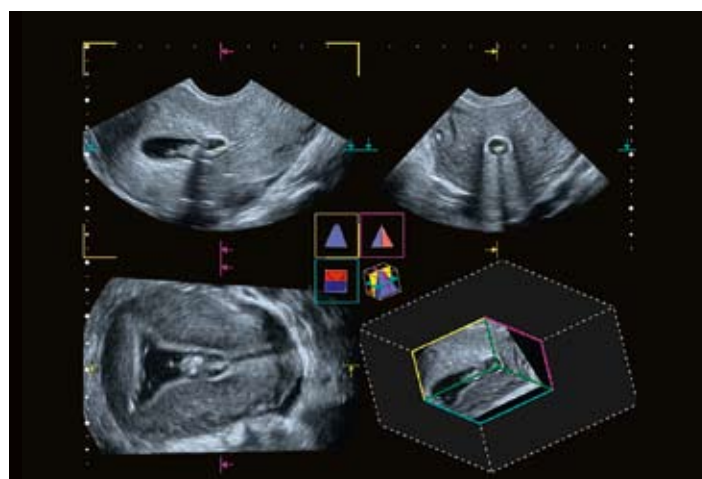


Fig. 2a: Multiplanar x, y and z (parasagittal, transverse, coronal) 2D anatomical sections plus block volume image display.

manipulated at leisure and anatomical and clinical findings closely evaluated. Modern 3D ultrasound systems offer a range of image formats (figures 2a–2e). This not only aids diagnosis itself but also greatly assists in terms of clinical communication of SIS findings. Manipulation of the surface rendering reference plane at both pre- and post storage stages is of significant practical importance (Clinical Case 1: figures d and e).

Clinical applications

Using saline infusion technique to separate and open up the walls of the uterine cavity enables high definition examination of its internal contour and clear delineation of intracavitary lesions to be carried out. In addition, it allows detailed ultrasound

evaluation of the peri-ovulatory endometrium and assessment of associated pathologies. As a result, SIS is now regarded in leading units as a routine, preliminary procedure used for investigating the cause of abnormal uterine bleeding. It is commonly carried out where standard TVS ultrasound suggests intracavitary pathology exists both in referrals presenting with atypical pv bleeding as well as asymptomatic cases.

More recent clinical application involves the use of SIS as part of the preliminary investigation of female infertility. SIS is very effective in excluding or confirming the existence of relevant anatomical malformations of the uterus as well as intracavitary/endometrial disorders. It is now common practice

to include SIS as a pre-requisite to IVF in order to ensure the physical environment into which the resulting embryo is inserted is normal and healthy. Its clinical role extends into other areas of reproductive medicine and in major units it is now established as a key element in the investigation of recurrent miscarriage. Again, the procedure readily identifies anatomical and other gynaecological issues involving the uterine cavity and associated with increasing risk of early pregnancy failure.

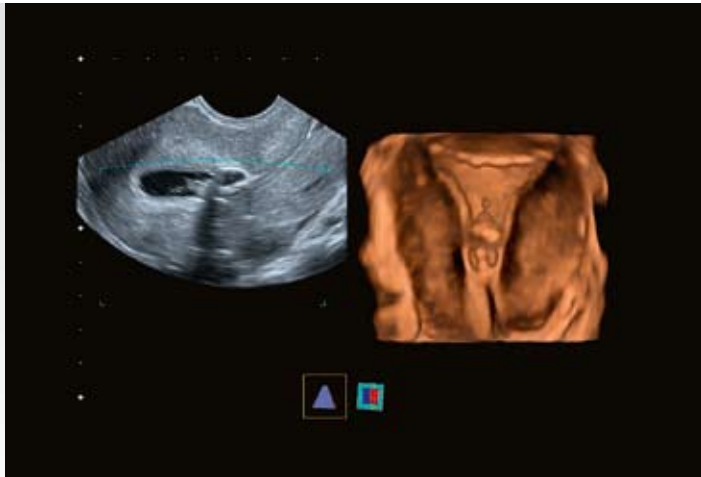


Fig. 2b: Composite 2D parasagittal plus surface rendered coronal anatomical sections.

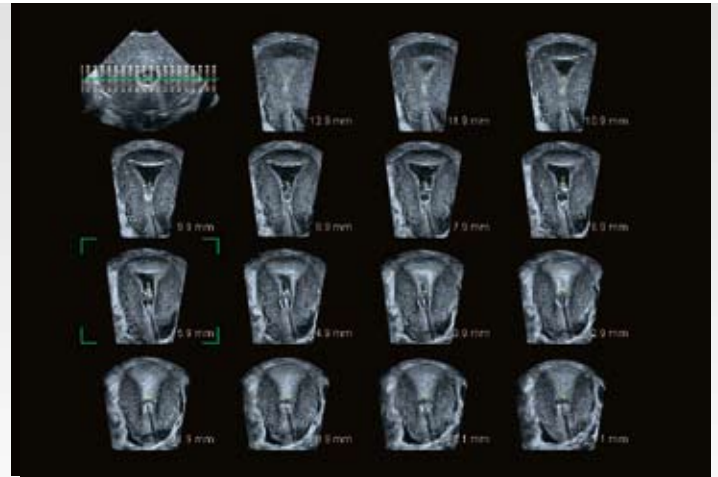


Fig. 2c: Multi View (tomographic) 3D anatomical sections – coronal 2D plane (15 anatomical slices).

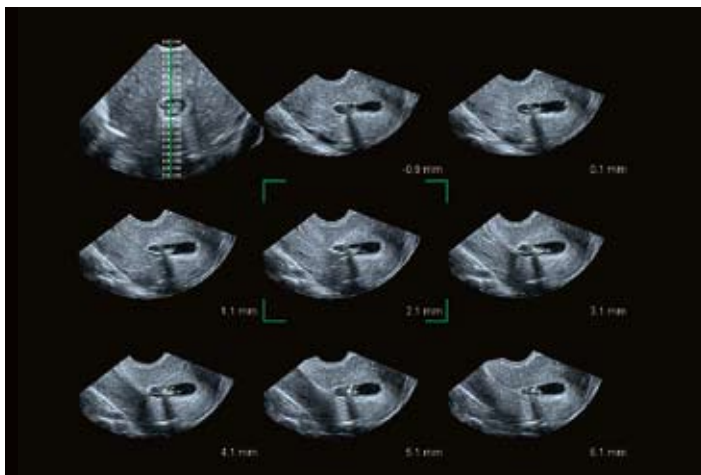


Fig. 2d: Multi View (tomographic) 3D anatomical sections – parasagittal 2D plane (8 anatomical slices).

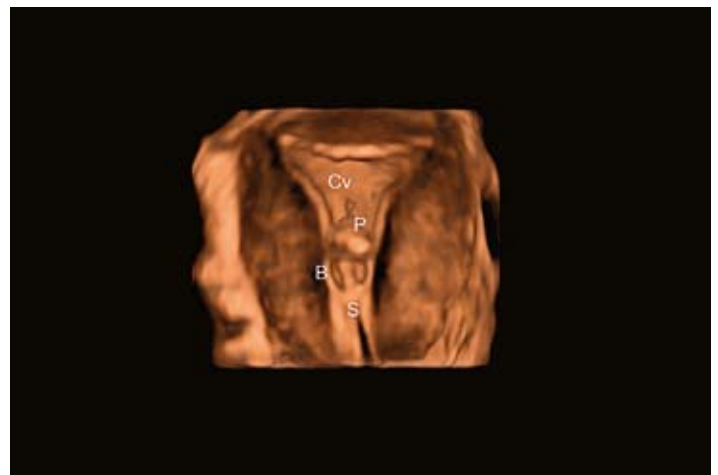

Fig. 2e: Surface rendered coronal anatomical section. The image demonstrates normal uterine cavity (Cv) size and shape with an endometrial polyp (P) located within the mid-lower cavity. The catheter balloon (B) and catheter stem (C) (shadow) can be clearly identified. These features can also be seen on figs. a–d.

Clinical Case 1 (Figures a–e):

The patient presented with abnormal uterine bleeding and a known history of uterine fibroids.

Figure a: The initial standard 2D TVS (parasagittal) section shows an obvious fundal fibroid (M) encroaching on the upper uterine cavity. The endometrium appears irregular in texture but otherwise unremarkable. The uterine cavity appears uniform and normal on routine TVS examination.

Figure b: Multiplanar reconstruction + block volume 3D images show irregular endometrial thickening with an obvious endometrial polyp (P).

Figure c: Multi View (tomographic) reconstruction (coronal 2D sections) confirm the findings suggested in figure b but also show that uterine fibroids (M) encroach upon but do not distort the cavity wall to any significant degree.

Figures d + e: The two composite (parasagittal 2D + coronal surface rendered) images show not just a single pedunculated endometrial polyp (P1) but several further broad-base polyps (P2). Note the different anatomical sections obtained in figures d + e as a result of varying the surface rendering reference plane (SR).

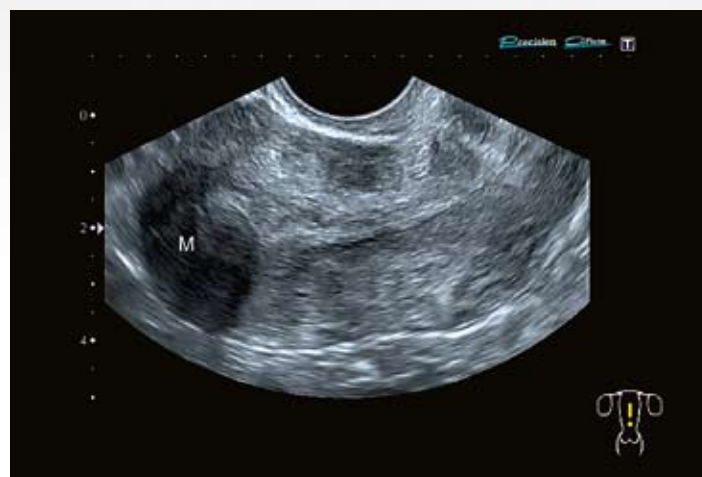

Fig. a

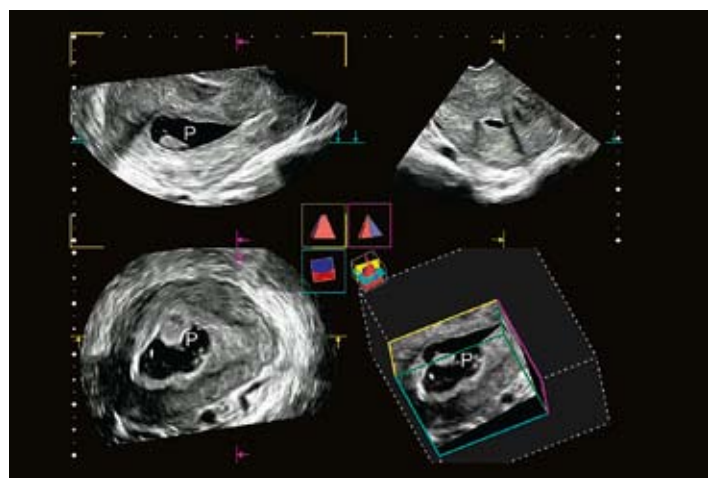


Fig. b

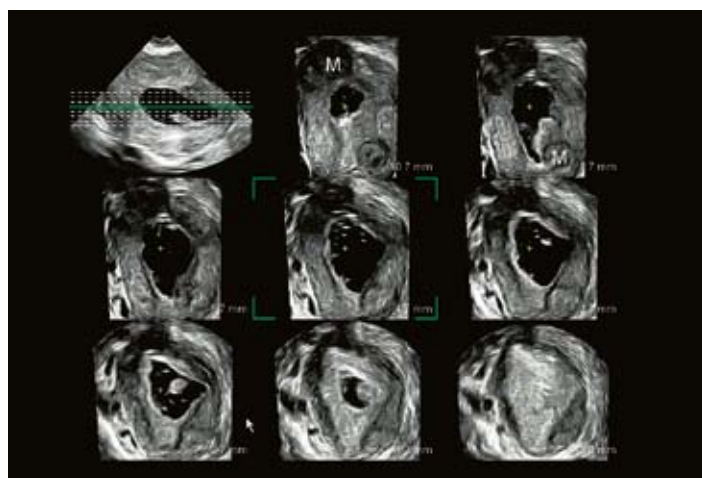


Fig. c

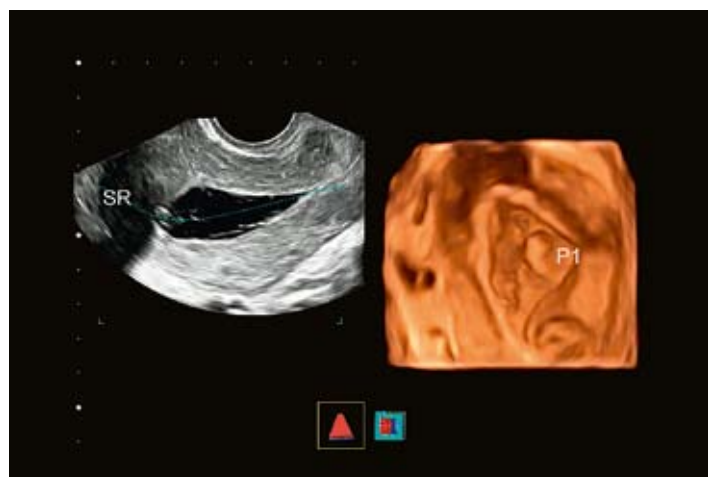


Fig. d

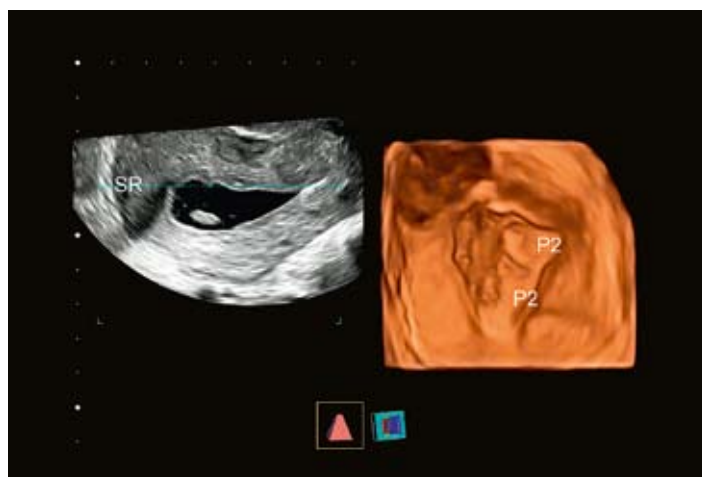


Fig. e

Clinical Case 2 (Figures a–e):

The patient presented for HSS (hysterosonoscopy) assessment of the Fallopian tubes – the examination routinely includes an SIS evaluation of the uterine cavity. The patient was attending as part of preliminary investigation for secondary infertility with no known gynaecological history.

Figure a: The initial standard 2D TVS (parasagittal) section shows normal uterine size and shape for age and parity with no obvious myometrial lesion(s). Nevertheless there appears to be a thickened, irregular endometrial texture.

Figure b: Multiplanar reconstruction + surface rendered images delineate a very obvious intracavitary fibroid (M) later confirmed at surgery.

Figures c + d: Multi View (tomographic) reconstruction (parasagittal + transverse 2D sections respectively) again clearly outline the fibroid (M). The latter shows a broad-base attachment of the lesion to the cavity wall.

Figure e: Composite (parasagittal 2D + surface rendered) images offer very precise imaging of the presence, size and location of the fibroid (M) within an otherwise normal uterine cavity (Cv).

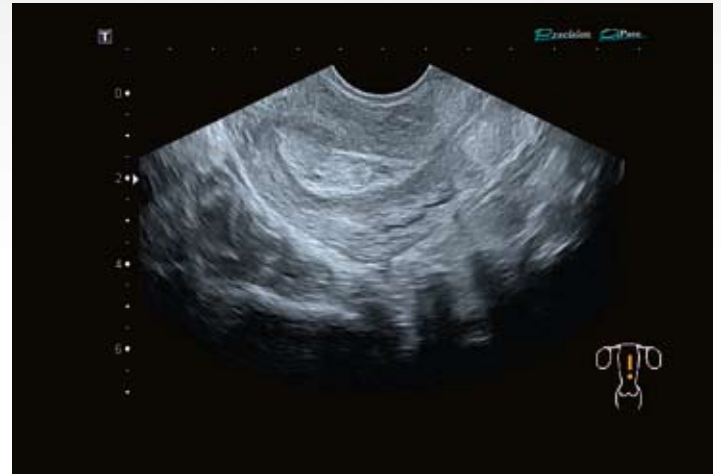

Fig. a

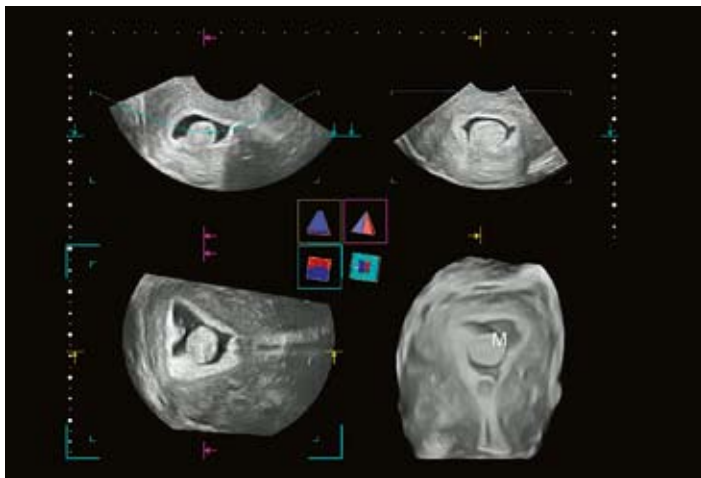


Fig. b

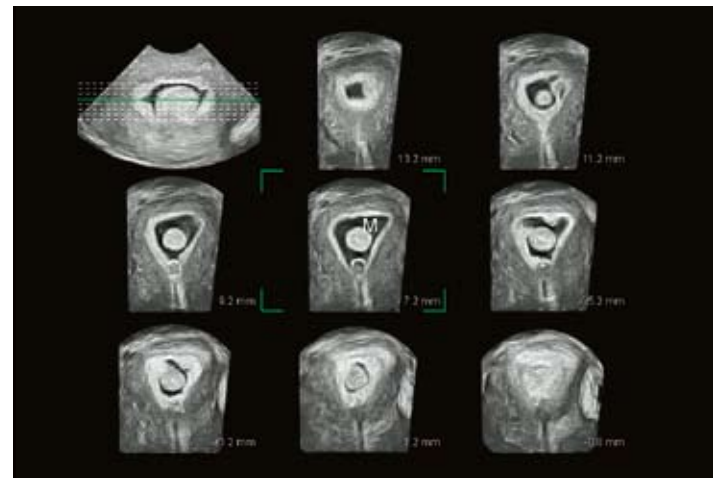


Fig. c

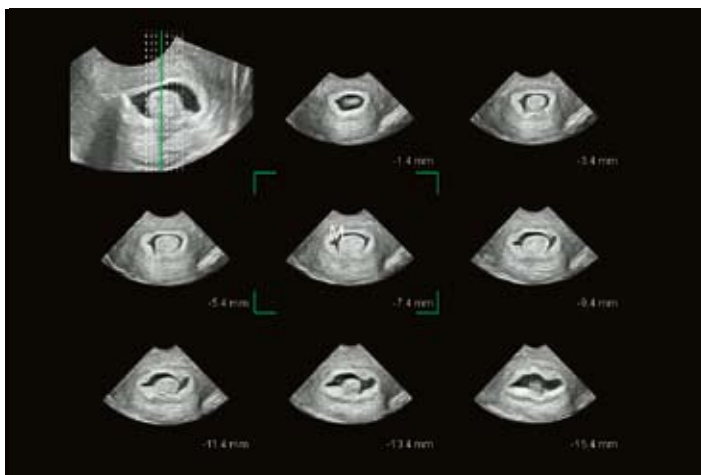


Fig. d

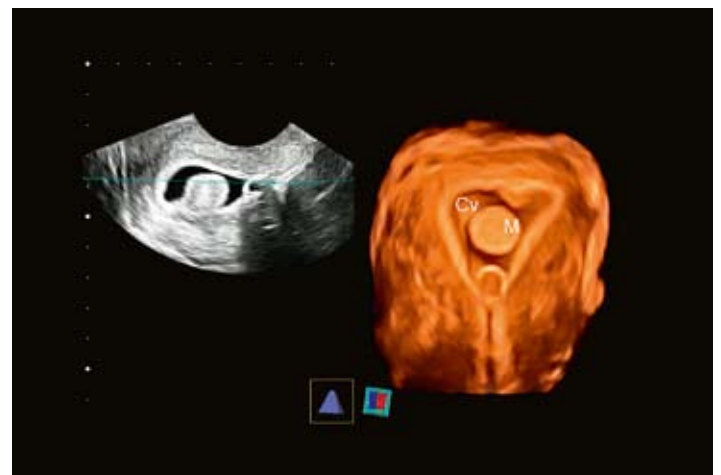


Fig. e

Clinical Case 3 (Figures a–e):

Fly Thru technology. SIS examination for abnormal uterine bleeding.

Figure a: Displays a standard 2D TVS (parasagittal) section of the uterus and uterine cavity with an obvious irregularity within the mid-upper cavity (Cv).

Figure b: Multiplanar reconstruction (x, y, z component) plus rendered (coronal) image. The images clearly demonstrate a large endometrial polyp (P1).

Figures c–e: Multiplanar reconstructions with Fly Thru displays showing a large polyp (P1) from different directions. Figure d clearly delineates the polyp pedicle (S1). The Fly Thru display in figure e delineates a further, smaller polyp (P2) of only a few millimetres in size adjacent to the polyp (P1). The pedicle (S2) associated with the smaller polyp (P2) is also seen, emphasising the degree of resolution obtained by this advanced 4D technique.

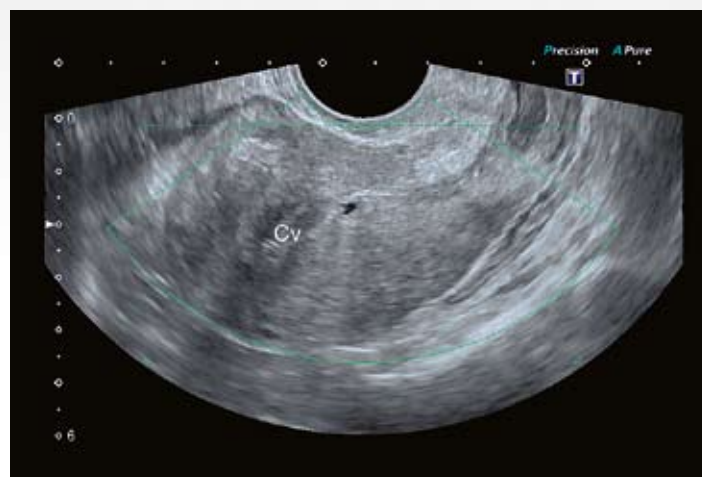


Fig. a

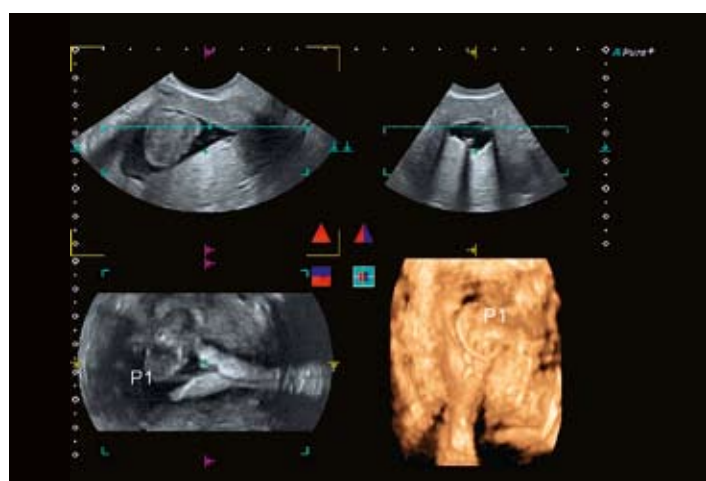


Fig. b

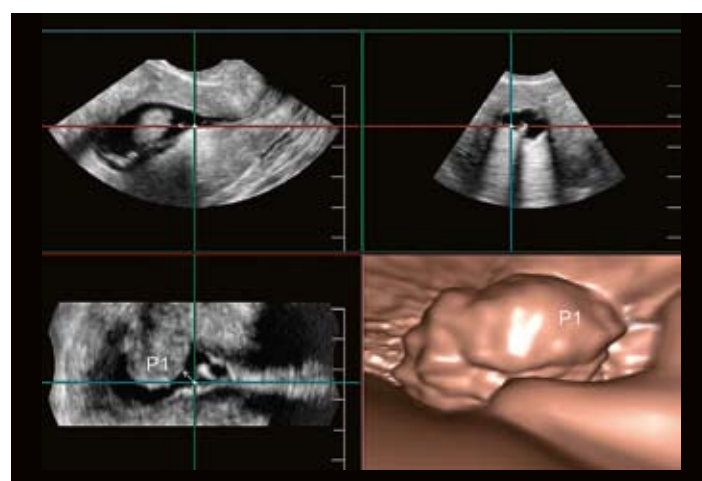


Fig. c

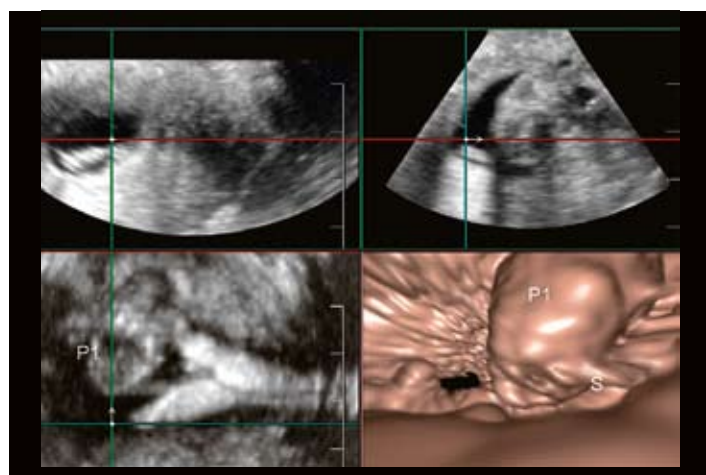


Fig. d

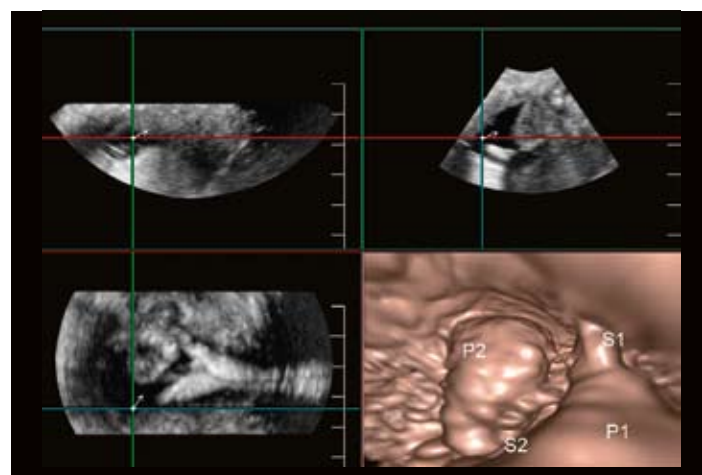


Fig. e

Ultrasound hysteroscopy:**Fly Thru technology**

The potential of 3D/4D TVS saline infusion sonohysterography to create an acceptable alternative to diagnostic hysteroscopy appears to be a realistic option as a result of very recent advances in Toshiba's Aplio ultrasound system. The Toshiba Leading Innovation programme has produced the Fly Thru imaging process.

Fly Thru technology uses the raw data obtained from a single 3D volume data set and creates cross-sectional ultrasound imaging which produces a visual display comparable to virtual reality endoscopy (Figure 3). The facility allows either manual or automatic navigation through the uterine cavity once it has been distended by saline solution. The internal contour, or any intracavitary lesion present, can then be visually assessed, unlike in the case of diagnostic hysteroscopy, from any direction.

The high quality images, produced from a single 3D volume acquired by the system, provide greater anatomical detail of the internal features of the uterine cavity and improved delineation of associated lesions using Fly Thru. It confirms with greater certainty those cases which need to be referred on for surgical (endoscopic) investigation and management.

The most common cause by far of abnormal uterine bleeding, especially in post-menopausal patients, is functional in nature and invariably involves atypical ovarian activity. Fly Thru appears to have a potentially crucial role in excluding intracavitary pathology and providing greater diagnostic confidence leading to more conservative clinical management in the majority of those patients.

Summary

- 3D TVS saline infusion sonohysterography is now an integral part of gynaecological ultrasound examination.

- Its diagnostic value and clinical impact in general gynaecological assessment principally involves the investigation of abnormal uterine bleeding. In addition it has a crucial role in aspects of fertility managements as well as investigation of recurrent miscarriage.
- The technical and clinical effectiveness of SIS procedure depends on the availability of modern, high quality 3D (volumetric) ultrasound facilities.
- In leading units, SIS has replaced diagnostic hysteroscopy with considerable benefits encompassing practical, diagnostic and financial aspects as well as levels of patient acceptability.
- Advanced innovations in Toshiba ultrasound technology has resulted in the development and practical utilisation of 4D Fly Thru imaging. The visual impact and diagnostic capability it offers gives considerable credence to the concept of ultrasound hysteroscopy with obvious clinical benefits.

Figure 3:

Fly Thru technology. A multiplanar (x, y, z components) plus Fly Thru display. An endometrial polyp (P) can be seen very clearly on the Fly Thru image as well as endometrial folds plus the Rt internal tubal ostium (T). The Fly Thru image is comparable to hysteroscopic visualisation of the relevant structures. Furthermore, navigation through the uterine cavity could be carried out either manually or automatically by the system itself.

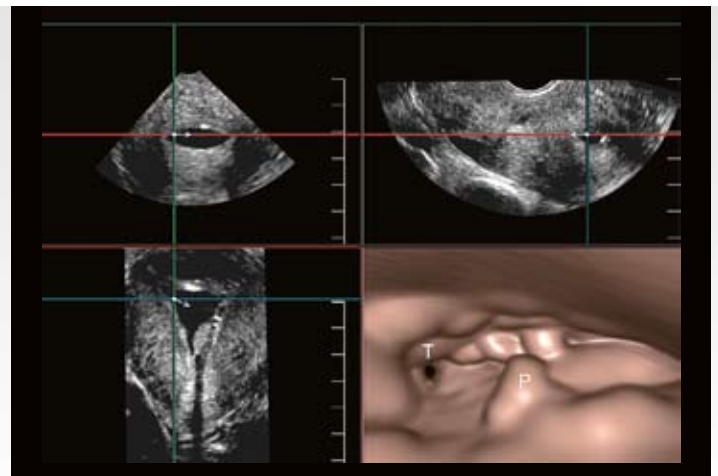


Fig. 3

TOSHIBA MEDICAL SYSTEMS CORPORATION

©Toshiba Medical Systems Corporation 2011 all rights reserved.

Design and specifications subject to change without notice.

08/2011 TWPUS0014EC.EU

Printed in Europe

www.toshiba-medical.eu



ULTRASOUND CT MRI X-RAY SERVICES